

Peculiarities of lymphocytes emigration from newborn thymus

O. A. Grygorieva, O. A. Apt

Zaporizhzhia State Medical University, Ukraine

Key words:

thymus,
lymphocytes,
lymphatic vessels,
mast cells.

Pathologia

2017; 14 (3), 358–363

DOI:

10.14739/2310-1237.
2017.3.118765

E-mail:

elengrig212@gmail.com

Introduction. Mechanisms of mass lymphocytes' emigration from thymus are still unclear. The process of lymphocytes migration and mechanisms, which provide it, form one of the important problems of immunomorphology.

Aim of the work: to establish the peculiarities of newborn thymus structure and to reveal pathways and mechanisms which provide lymphocytes' emigration from thymus.

Materials and methods. Morphological, histological and histochemical analyses of 160 rats' thymuses from birth up to the 7th day after birth were conducted and discussed. The animals were handled according to the European Commission Directive (86/609/EEC). The profound microscopic analysis of cell contents, lymphatic vessels morphology in morpho-functional areas of rats' thymuses during the first week after birth in 4 hours interval was carried out. All quantitative results were estimated by the statistic methods.

Results. It is settled that thymus specific density tightly depends on the quantity of degranulated mast cells, absolute quantity of microcirculatory vessels, especially of lymphatic ones. The index of specific density, lymphocyte-epithelial index change wavy during the first week after birth every 12 hours. These changes are followed by the changes of extracellular matrix structure, absolute quantity of small lymphocytes in thymic cortex and lymphocytes' adhesive properties. The key periods are: from 0 till 2, from 12 till 16, and from 108 till 120 hours after birth. At that time discrete migration of lymphocytes from the thymus occurs through paravascular lymphatic vessels. After temporal edema reduction, lymphatic vessels turn to be empty, their quantity decreases.

Conclusion. Therefore, emigration of lymphocytes from thymus takes place through lymphatic vessels on the top of periodical short-term local edema.

Ключові слова:

тимус, лімфоцити,
лімфатичні судини,
тучні клітини.

Патологія. – 2017. –

Т. 14, № 3(41). –
С. 358–363

Особливості еміграції лімфоцитів із тимуса

О. А. Григор'єва, О. А. Апт

Сьогодні активно досліджуються механізми еміграції тимоцитів із тимуса на периферію, але вони й досі залишаються не вивченими.

Мета роботи – описати структурні особливості будови тимуса новонароджених, визначити шляхи та механізми, що забезпечують процес еміграції лімфоцитів із тимуса.

Матеріали та методи. Здійснили морфологічне, гістологічне, гістохімічне дослідження препаратів 160 тимусів білих щурів від моменту народження до 7 доби життя. Під час роботи з експериментальними тваринами керувалися «Європейською конвенцією з захисту хребетних тварин, які використовуються в експериментальних і інших наукових цілях» (Страсбург, 18.03.1986). Догляд за тваринами здійснювали відповідно до норм і вимог, що розроблені згідно з кодексом Ради міжнародних медичних організацій «Міжнародні рекомендації для проведення медико-біологічних досліджень з використанням тварин». Досліджували кількість лімфоцитів, епітеліоретикулоцитів, тучних клітин, кровоносних і лімфатичних судин у морфофункціональних ділянках тимуса щурів протягом першого тижня після народження через інтервал 4 години. Кількісні дані опрацювали методами варіаційної статистики.

Результати. Запропонували гіпотезу міграції тимоцитів із тимуса через лімфатичні судини під час періодичного короточасного локального набряку. Встановлено, що у новонароджених, починаючи з 8 години життя, кожні 12 годин збільшуються питома щільність тимуса, абсолютна кількість судин мікроциркуляторного річища, особливо лімфатичних, лімфо-епітеліальний індекс, кількість тучних клітин та їхніх дегранулятивних форм. Змінюються структура екстрацелюлярної матриці, внутрішньотимічного мікросередовища та адгезивні властивості лімфоцитів. Абсолютна кількість дрібних лімфоцитів у корковій речовині тимуса хвилеподібно коливається. Всі ці зміни яскраво виражені з 0 до 2, із 12 до 16, з 108 до 120 годин післянатального життя. У цей період паравазальні лімфатичні судини щільно заповнені лімфоцитами, тобто відбувається дискретна міграція лімфоцитів із тимуса. Після швидкого зменшення набряку кількість лімфатичних судин падає, вони стають порожніми.

Висновки. У тимусі новонародженого спостерігається періодичний короточасний локальний набряк, на піку якого виникає дискретна міграція лімфоцитів із тимуса.

Ключевые слова:

тимус, лимфоциты,
лимфатические
сосуды,
тучные клетки.

Патологія. – 2017. –

Т. 14, № 3(41). –
С. 358–363

Особенности эмиграции лимфоцитов из тимуса

Е. А. Григорьева, О. А. Апт

Механизмы, обеспечивающие массовую эмиграцию лимфоцитов из тимуса, до сих пор остаются не изученными. Процесс миграции лимфоцитов и механизмы, обеспечивающие его, формируют одну из важных задач иммуноморфологии.

Цель работы – описать структурные особенности строения тимуса новорожденных, выявить пути и механизмы, обеспечивающие эмиграцию лимфоцитов из тимуса.

Материалы и методы. Провели морфологическое, гистологическое и гистохимическое изучение препаратов 160 тимусов белых крыс от момента рождения до 7 суток жизни. При работе с животными руководствовались «Европейской конвенцией по защите позвоночных животных, которые используются в экспериментальных и других научных целях» (Страсбург, 18.03.86). Уход за животными осуществляли в соответствии с нормами и требованиями, разработанными согласно кодексу Совета международных медицинских организаций «Международные рекомендации для проведения медико-биологических исследований с использованием животных». Исследовали количество лимфоцитов, эпителио-ретикулоцитов, тучных клеток, кровеносных и лимфатических сосудов в морфофункциональных зонах тимуса крыс в течение первой недели жизни через 4-часовые интервалы. Полученные количественные данные обработаны методами вариационной статистики.

Результаты. На основании полученных данных предложена гипотеза о механизмах эмиграции лимфоцитов из тимуса через лимфатические сосуды во время периодического кратковременного местного отека. Установлено, что у новорожденных, начиная с 8 часов после рождения, каждые 12 часов увеличиваются удельная плотность тимуса, абсолютное количество сосудов микроциркуляторного русла, особенно лимфатических, лимфо-эпителиальный индекс, количество тучных клеток и их дегранулированных форм. Изменяется структура экстрацеллюлярного матрикса, внутритимического микроокружения и адгезивная способность лимфоцитов. Абсолютное количество малых лимфоцитов в коре тимуса волнообразно колеблется. Все эти изменения были максимально выражены с 0 до 2, с 12 до 16, со 108 до 120 часов постнатальной жизни. На протяжении этих периодов паравазальные лимфатические сосуды заполнены лимфоцитами. Таким образом, имеет место дискретный тип миграции лимфоцитов из тимуса. После быстрого уменьшения отека количество лимфатических сосудов сокращается, они опустевают.

Выводы. В тимусе новорожденных наблюдается периодический кратковременный местный отек, на пике которого происходит дискретная миграция лимфоцитов из тимуса.

Introduction

During the first hours after birth settling of peripheral lymphoid organs by T-lymphocytes takes place [7,8]. Among T-lymphocytes, which settle peripheral lymphoid organs during first hours after birth there are immunological immature T-lymphocytes, $\gamma\delta$ -T-lymphocytes, which conduct function of morphogenesis control in peripheral lymphoid and non-lymphoid organs [7]. Mechanisms of mass lymphocytes' emigration from thymus are still unclear. Nowadays lymphocytes migration and mechanisms, which provide it, are of great interest [4,5,8]. Attention is paid to the entrance of pre-T-lymphocytes into thymus [3,6] and to the intrathymical migration of lymphocytes during maturation and differentiation [1,2]. Emigration of lymphocytes from thymus is less understood. Pathways and mechanisms, which provide it, are also still unclear.

According to the data of '70s of last century, post-capillary veins of thymus medulla are the main place of lymphocytes' emigration. According to Yarilin's opinion (1991) cortico-medullary junction of thymus is the main place of T-lymphocytes' emigration from thymus after they have gone positive or negative selection and differentiation [11]. Forced emigration of T-lymphocytes from thymus before and after birth according to this data is provided by development of cholinergic innervations of thymus. Mori et. al. (2007) consider that perivascular spaces of cortico-medullary junction is a place of pre-T-cells immigration into the thymus as well as a place of mature T-cells emigration from the thymus [4]. But the problem of perivascular spaces structure and origin is still unsolved.

Aim of the work: to establish the peculiarities of newborn thymus structure and to reveal pathways and mechanisms which provide lymphocytes' emigration from thymus.

Materials and methods

Object of investigation – 173 rats' thymuses from the birth up to the 7th day after birth. Newborns were obtained from rats with established day of pregnancy. Newborns were

born on the 23–24th day of pregnancy at different daytime. All animals were kept under standard stable conditions (temperature: 20 ± 2 °C, relative humidity: 50 ± 5 %, lighting from 8:00 to 20:00, a Panlab balanced diet and water ad libitum). The animals were handled according to the European Commission Directive (86/609/EEC). Rats were sacrificed by decapitation under ether narcosis with interval of 4 hours up to the 48th hour after birth and with interval of 12 hours up to the 7th day after birth. Shape, mass and volume of thymus were investigated, specific density of thymus was estimated. For histological investigation of thymus organs were fixed in Bouen solution. Samples were stained with PAS-reactive, with hematoxylinum-eosinum. Cell contents of thymus was analyzed, lymphocyte-epithelial index was estimated. Microcirculatory vessels of thymus were revealed under impregnation of samples by silver carbonate after Laidlaw. Absolute number of mast cells and its dynamics in thymus capsule, interlobular septa and along vessels of cortico-medullary region were examined. Glycosaminoglycans were revealed by staining of samples with alcian blue (pH 2.6) after Scott & Dorling. All the quantitative results were estimated by the statistic methods, $M \pm m$, the results were considered significant at $P < 0.05$.

Results and discussion

Specific density of newborn thymus is 1.066 ± 0.020 mg/mm³. The majority of cells is represented by small lymphocytes. The highest solidity of cells is in cortex (55.50 ± 6.26). Maximal lymphocyte-epithelial index is also in this morpho-functional zone (29.5). By means of histological samples staining with silver carbonate after Laidlaw we came to the conclusion that perivascular spaces of medulla and cortico-medullary junction of the thymus were perivascular lymphatic vessels, evidence of which was explained by Sviridov (1966) [10]. Maximal contents of microcirculatory vessels are revealed in cortico-medullary junction (Table 2). Capillaries are predominated over. Absolute number of perivascular lymphatic vessels is 5.60 ± 0.22 .

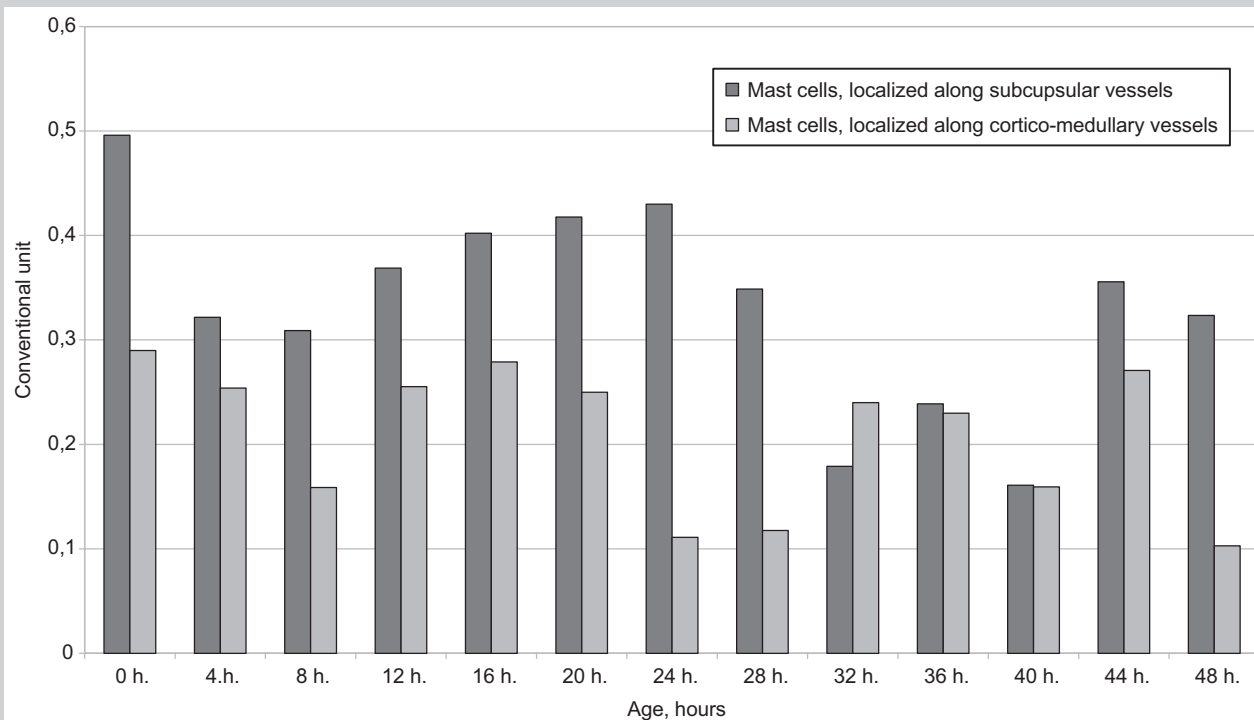


Fig. 1. Dynamics of mast cells degranulation index in rat thymus in early postnatal period.

Number of mast cells is nearly maximal (Table 3). Mast cells are settled in groups consisting of 3–4 cells in the inner cortical region and along vessels of thymus capsule, where its specific solidity is higher (1.36 ± 0.31) than along blood vessels of cortico-medullary junction (0.91 ± 0.20). The number of degranulated mast cells situated along capsular vessels is the highest one (Fig. 1).

All types of glycosaminoglycans are present in thymus. Contents of glycosaminoglycans in newborn thymus are rather high. Sulfated glycosaminoglycans are predominated. Alcianophilic contents are present in thymus epithelial channels up to 6 hour after birth. Contents of hyaluronic acid increase in the contents of thymus extracellular matrix, in interlobular septa, in the walls of blood vessels up to 6 hour after birth. This fact causes the increasing of hydrophilicity of thymus.

During 8 hours after birth specific density of thymus decreases (Table 1). Lymphocyte-epithelial index also decreases (Fig. 2).

The number of perivascular lymphatic vessels decreases nearly by 3.5 times in medulla and in cortico-medullary junction (Table 2). Absolute number of mast cells decreases (Table 3) and the number of degranulated mast cells also decreases (Fig. 1).

At the 16th hour after birth specific density of thymus is the highest one (Table 1), lymphocyte-epithelial index in cortex is the lowest one (Fig. 2), number of perivascular lymphatic vessels increases in medulla as well as in cortico-medullary junction (Table 2). Degranulative index of mast cells increases (Fig. 1), but the number of mast cells itself a little bit decreases (Table 3). Contents of hyaluronic acid in interlobular septa, in blood vessels' walls are still high up to the end of the 1st day after birth.

Amount of hyaluronic acid in the contents of epithelial congestions increases.

At the 20th hour after birth rapid increasing of lymphocyte-epithelial index in cortex is revealed. This index slowly decreases up to the 36th hour after birth, then up to the 108th hour of postnatal life it hardly changes. From the 108th hour after birth up to the 120th hour after birth lymphocyte-epithelial index is still low, but up to the 132nd hour of postnatal life it increases and hardly changes up to the end of the 1st week after birth (Fig. 2).

Specific density of thymus changes wavy during the first week of postnatal life (Table 1). The highest specific density is fixed at the 16th, 28th, 72nd and 120th hour after birth. Number of perivascular lymphatic vessels also changes wavy during the first week after birth. The highest number of this kind of microcirculatory vessels is revealed on the 1st, 16th, 36th, 72nd and 144th hour of postnatal life (Table 2). The most marked changes of mast cells' degranulative index are revealed during two days after birth and from the 108th up to the 132nd hour of postnatal life (Fig. 1). The contents and composition of thymus extracellular matrix glycosaminoglycans change up to the end of the 1st day of life. Increasing of sulfated glycosaminoglycans amount takes place.

Increasing of capillary permeability is the base of any edema. It may be caused by different effects, one of which is increasing of histamine level in blood plasma and in extracellular matrix of tissues. Increasing of fluid amount in interstitium leads to passive opening of lymphatic vessels by means of anchor filaments. High index of thymus volume on the background of low index of relative mass and specific density is revealed during first hours after birth [9]. Later on relative mass of thymus and its specific

Table 1. Dynamics of absolute, average mass of thymus, its specific density and volume in early postnatal period

Age of animals, hours	Average mass of the rats, mg	Absolute thymus mass, mg	Average thymus mass, %	Specific gravity of thymus, mg/mm ³	Thymus volume, mm ³
0 (n = 7)	5664.29 ± 461.23	9.07 ± 1.43	0.16 ± 0.02	1.066 ± 0.020	8.45 ± 1.37
2 (n = 6)	5651.67 ± 642.56	8.50 ± 1.40	0.15 ± 0.02	1.064 ± 0.020	8.02 ± 1.51
4 (n = 8)	5892.86 ± 522.86	11.43 ± 2.41	0.19 ± 0.03	1.065 ± 0.010	10.74 ± 2.27
6 (n = 6)	5311.67 ± 305.23	10.08 ± 0.59	0.19 ± 0.01	1.068 ± 0.030	9.44 ± 0.59
8 (n = 6)	5400.00 ± 879.56	9.92 ± 2.44	0.18 ± 0.01	1.078 ± 0.010	9.19 ± 1.78
10 (n = 6)	5150.29 ± 527.68	8.45 ± 1.37	0.17 ± 0.01	1.080 ± 0.010	7.89 ± 1.54
12 (n = 6)	4834.00 ± 695.18	7.70 ± 1.35	0.16 ± 0.01	1.082 ± 0.020	7.11 ± 1.15
16 (n = 6)	6750.00 ± 134.19	11.25 ± 1.64	0.17 ± 0.02	1.082 ± 0.010	10.27 ± 1.64
20 (n = 6)	6451.67 ± 1086.58	11.75 ± 1.56	0.18 ± 0.03	1.080 ± 0.010	12.40 ± 1.81
24 (n = 6)	5446.67 ± 853.99	9.83 ± 0.85	0.18 ± 0.01	1.074 ± 0.020	9.77 ± 0.25
28 (n = 6)	5698.33 ± 498.44	9.42 ± 1.14	0.17 ± 0.03	1.099 ± 0.030	8.60 ± 1.12
32 (n = 7)	6118.57 ± 251.49	9.86 ± 1.99	0.16 ± 0.03	1.084 ± 0.020	9.09 ± 1.84
36 (n = 7)	6390.00 ± 938.90	9.25 ± 1.54	0.15 ± 0.02	1.057 ± 0.010	8.77 ± 1.55
40 (n = 6)	7556.67 ± 736.29	13.75 ± 1.98	0.18 ± 0.01	1.052 ± 0.020	13.11 ± 2.05
44 (n = 7)	8342.86 ± 806.07	15.36 ± 2.89	0.18 ± 0.03	1.063 ± 0.020	14.46 ± 2.79
48 (n = 6)	5566.00 ± 412.38	10.60 ± 2.39	0.19 ± 0.04	1.071 ± 0.020	9.92 ± 2.28
54 (n = 6)	5895.00 ± 371.84	10.66 ± 1.46	0.18 ± 0.02	1.055 ± 0.010	10.10 ± 1.34
60 (n = 5)	7974.00 ± 745.36	16.00 ± 2.15	0.20 ± 0.01	1.048 ± 0.020	15.33 ± 2.33
66 (n = 6)	8008.33 ± 999.49	15.83 ± 2.34	0.20 ± 0.01	1.050 ± 0.010	15.03 ± 2.24
72 (n = 7)	7890.00 ± 1018.83	15.71 ± 2.05	0.20 ± 0.13	1.059 ± 0.020	14.81 ± 2.06
84 (n = 6)	6892.0 ± 617.27	13.90 ± 2.75	0.20 ± 0.04	1.067 ± 0.010	13.03 ± 2.59
96 (n = 6)	9248.00 ± 1224.30	19.50 ± 2.66	0.21 ± 0.01	1.070 ± 0.010	18.24 ± 2.49
108 (n = 6)	9762.00 ± 2281.95	21.20 ± 5.47	0.22 ± 0.03	1.060 ± 0.010	20.04 ± 5.28
120 (n = 6)	9978.33 ± 1375.05	22.92 ± 4.47	0.23 ± 0.02	1.067 ± 0.011	21.54 ± 4.39
132 (n = 7)	11071.67 ± 721.66	22.58 ± 5.37	0.20 ± 0.04	1.059 ± 0.008	21.38 ± 5.21
144 (n = 6)	11621.67 ± 996.96	26.58 ± 1.31	0.23 ± 0.02	1.058 ± 0.003	25.13 ± 1.32
156 (n = 5)	12520.00 ± 1715.3	27.10 ± 6.64	0.21 ± 0.04	1.062 ± 0.010	25.55 ± 6.32
168 (n = 5)	11942.0 ± 1406.48	27.20 ± 1.29	0.23 ± 0.02	1.052 ± 0.006	25.85 ± 1.66

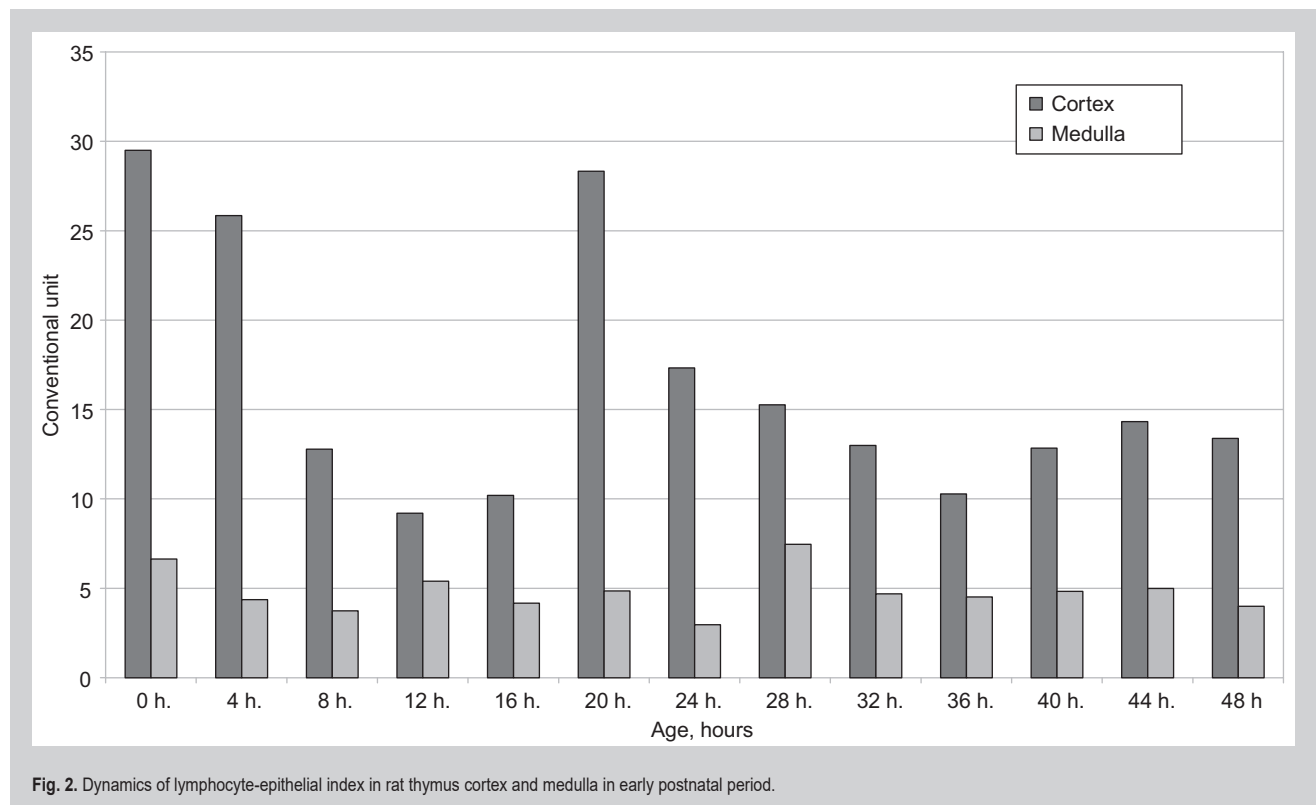
**Fig. 2.** Dynamics of lymphocyte-epithelial index in rat thymus cortex and medulla in early postnatal period.

Table 2. Dynamics of microcirculatory vessels number in rat thymus (per 8640 mcm²) in early postnatal period

Animals age, hours	"Peripheral" parts of thymus lobules		"Central" parts of thymus lobules		
	Total number of microcirculatory vessels	Blood capillaries	Total number of microcirculatory vessels	Blood capillaries	Perivascular lymphatic capillaries
0	18.72 ± 1.44	14.40 ± 2.20	27.69 ± 4.16	16.00 ± 4.80	5.60 ± 0.22
2	16.00 ± 3.30	11.60 ± 2.20	27.50 ± 2.75	15.50 ± 2.75	5.50 ± 1.38
4	16.70 ± 0.71	11.40 ± 3.90	16.89 ± 3.67	8.44 ± 2.44	2.2 ± 0.10
6	14.29 ± 3.14	10.57 ± 1.57	15.20 ± 2.75	5.60 ± 0.55	2.60 ± 0.55
8	21.20 ± 3.30	13.20 ± 1.10	16.00 ± 2.75	6.67 ± 1.83	1.33 ± 0.21
10	18.43 ± 1.44	10.56 ± 0.92	16.34 ± 2.06	6.89 ± 0.61	2.25 ± 0.15
12	15.67 ± 0.92	8.33 ± 1.83	17.30 ± 0.92	7.00 ± 1.83	3.30 ± 0.05
16	16.00 ± 1.83	12.00 ± 1.83	16.00 ± 3.67	6.67 ± 0.15	5.33 ± 1.03
20	15.50 ± 1.38	11.00 ± 1.38	21.33 ± 2.06	8.00 ± 0.61	4.59 ± 0.61
24	14.57 ± 0.78	9.14 ± 0.78	17.75 ± 2.06	7.50 ± 1.38	5.00 ± 0.69
28	16.00 ± 0.92	11.67 ± 1.83	17.25 ± 2.06	7.00 ± 1.33	2.25 ± 0.69
32	15.33 ± 1.83	13.33 ± 0.92	20.25 ± 2.06	11.50 ± 1.33	2.50 ± 0.69
36	15.67 ± 0.92	13.30 ± 1.83	17.33 ± 1.83	8.33 ± 0.92	4.50 ± 0.92
40	14.75 ± 1.38	12.00 ± 1.38	22.00 ± 1.83	12.67 ± 1.83	3.33 ± 0.92
44	12.50 ± 0.10	9.50 ± 1.38	20.67 ± 1.83	14.00 ± 1.83	2.67 ± 0.92
48	14.50 ± 0.69	8.75 ± 0.69	25.20 ± 2.20	14.40 ± 2.20	4.50 ± 1.10
54	14.80 ± 1.11	12.40 ± 2.20	21.33 ± 1.83	13.30 ± 1.83	2.33 ± 0.92
60	16.30 ± 1.83	13.00 ± 1.83	20.50 ± 1.38	12.25 ± 1.38	2.50 ± 0.69
66	11.43 ± 1.57	9.71 ± 1.57	22.00 ± 4.40	12.80 ± 3.30	4.80 ± 1.10
72	13.30 ± 1.83	9.33 ± 0.92	19.71 ± 1.57	8.57 ± 0.79	4.00 ± 0.79
84	12.20 ± 0.92	7.67 ± 0.92	21.75 ± 3.44	15.00 ± 2.75	4.00 ± 1.38
96	12.57 ± 1.57	7.71 ± 1.57	22.86 ± 1.57	10.86 ± 1.57	3.71 ± 0.79
108	14.25 ± 1.38	6.25 ± 0.69	23.60 ± 1.57	8.80 ± 2.20	4.11 ± 1.10
120	9.20 ± 1.1	6.00 ± 1.10	21.67 ± 1.83	10.33 ± 1.83	4.00 ± 0.92
132	12.00 ± 1.57	11.14 ± 1.57	26.00 ± 2.75	12.00 ± 1.83	3.67 ± 0.92
144	14.00 ± 1.82	8.67 ± 1.82	24.80 ± 2.20	12.80 ± 2.20	3.71 ± 0.79
156	14.00 ± 0.69	11.75 ± 1.33	18.00 ± 2.75	8.50 ± 0.69	3.75 ± 0.69
168	11.00 ± 1.38	6.00 ± 1.38	20.33 ± 0.92	10.00 ± 1.83	2.33 ± 0.92

Table 3. Dynamics of absolute number of mast cells in rat thymus (per 8640 mcm²) in early postnatal period

Animals age, hours	Mast cells, localized below thymus capsule and along interlobular septas of thymus	Mast cells, localized along vessels of cortico-medullary region
0	2.56 ± 0.59	1.70 ± 0.37
2	1.88 ± 0.43	1.74 ± 0.30
4	1.60 ± 0.35	1.09 ± 0.29
6	1.67 ± 0.37	0.72 ± 0.26
8	1.77 ± 0.36	1.36 ± 0.29
10	1.98 ± 0.37	1.24 ± 0.26
12	2.15 ± 0.39	1.13 ± 0.35
16	1.98 ± 0.38	0.92 ± 0.29
20	1.53 ± 0.48	1.40 ± 0.39
24	1.74 ± 0.43	0.95 ± 0.30
28	1.64 ± 0.39	0.89 ± 0.31
32	1.02 ± 0.36	0.92 ± 0.31
36	1.06 ± 0.35	0.85 ± 0.26
40	1.57 ± 0.41	1.23 ± 0.34
44	1.84 ± 0.56	0.95 ± 0.33
48	1.43 ± 0.47	1.47 ± 0.48
54	2.05 ± 0.57	1.81 ± 0.50
60	0.82 ± 0.32	0.65 ± 0.30
66	1.06 ± 0.39	0.82 ± 0.31
72	1.33 ± 0.39	0.78 ± 0.29
84	1.43 ± 0.41	0.51 ± 0.22
96	1.67 ± 0.50	1.50 ± 0.49
108	1.53 ± 0.37	0.65 ± 0.24
120	2.12 ± 0.52	1.10 ± 0.36
132	1.79 ± 0.48	1.02 ± 0.27
144	1.79 ± 0.47	0.96 ± 0.30
156	2.28 ± 0.51	0.99 ± 0.33
168	0.96 ± 0.28	0.51 ± 0.23

density increase but thymus volume decreases (*Table 1*). Increasing of specific density index is also fixed at the 24th, 48th, 64th hours after birth.

Tissue of newborns thymus is under conditions of respiratory acidosis which takes place during transferring of the body into extrauterine conditions. Increasing of thymus volume may be explained because of its hydration, that is by development of physiological edema.

During the first hours after birth the number of perivascular lymphatic vessels is the highest. On this background erythrocytes' capillary sludge is usually revealed. Contents of mast cells in newborn thymus are also high. Degranulative index of mast cells is the highest in newborns. Histamine secretion into extracellular matrix of thymus takes place during mast cells degranulation. Histamine increases capillary permeability as well as permeability of extracellular matrix and increases hydrophilicity of thymus tissue.

All the mentioned reflects development of thymus tissue edema. In the absence of inflammation or any other tissue impairment, hyperhydration of tissue may be concerned as physiological edema, which takes place in newborns tissues as reflection of respiratory acidosis.

During the first hours after birth lymphocyte-epithelial index rapidly decreases, but the number of destroyed cells is not increased. This fact points on lymphocytes' emigration from thymus. Obtained results coordinate with our previous results of Voloshyn et al. (2002, 2005) for lymphocytes' entrance in spleen, skin and other lymphoid and nonlymphoid organs during this period of life [7,8].

Lymphocytes have got less energy capacity that is why they cannot themselves provide massive active emigration from thymus. So, lymphocytes' emigration from thymus must be a passive process. Opened lymphatic vessels are a convenient way. During edema development interstitial pressure changes and lymphocytes with interstitial fluid stream pass through lymphatic vessels and leave the thymus. This universal mechanism is caused by periodical thymus edema (increasing of tissue hydration).

Conclusions

It is established that lymphocytes emigration from thymus takes place through perivascular lymphatic vessels and is provided by development of discrete local physiological edema.

Сведения об авторах:

Григорьева Е. А., д-р мед. наук, профессор, зав. каф. анатомии человека, оперативной хирургии и топографической анатомии, Запорожский государственный медицинский университет, Украина.

Апт О. А., канд. мед. наук, доцент каф. анатомии человека, оперативной хирургии и топографической анатомии, Запорожский государственный медицинский университет, Украина.

Конфлікт інтересів: відсутній.

Conflicts of Interest: authors have no conflict of interest to declare.

Надійшло до редакції / Received: 07.09.2017

Після доопрацювання / Revised: 28.09.2017

Прийнято до друку / Accepted: 02.10.2017

References

- [1] Crisa, L., Cirulli, V., Ellisman, M. H., Ishii, J. K., Elices, M. J., & Salomon, D. R. (1996) Cell adhesion and migration are regulated at distinct stages of thymic T cell development: the roles of fibronectin, VLA4, and VLA5. *J. Exp. Med.*, 184(1), 215–28. doi: 10.1084/jem.184.1.215.
- [2] Jotereau, F., Heuze, F., Salomon-Vie, V., & Gascan, H. (1987) cell kinetics in the fetal mouse thymus: precursor cell input, proliferation, end emigration. *J. of Immunology*, 138(4), 1026–1030.
- [3] Kawakami, N., Nishizawa, F., Sakane, N., Iwao, M., Tsujikawa, K., Ikawa, M., et al. (1999) Roles of integrins and CD44 on the adhesion and migration of fetal liver cells to the fetal thymus. *J. of Immunology*, 163, 3211–3216.
- [4] Mori, K., Itoi, M., Tsukamoto, N., Kubo, H., & Amagai, T. (2007) The perivascular space as a path of hematopoietic progenitor cells and mature T cells between blood circulation and the thymic parenchyma. *International Immunology*, 19(6), 745–753. doi: 10.1093/intimm/dxm041.
- [5] Weinreich, M. A., & Hogquist, K. A. (2008) Thymic emigration: when and how T cells leave home. *The journal of immunology*, 181, 2265–2270. doi: <https://doi.org/10.4049/jimmunol.181.4.2265>.
- [6] Wilkinson, B., Owen, J. J., & Jenkinson, E. J. (1999) Factors regulating stem cell recruitment to the fetal thymus. *J. Immunology*, 162, 3873–3881.
- [7] Voloshyn, M. A. (2005) Limfotsyt – faktor morfoheneza [Lymphocyte is a factor of morphogenesis]. *Zaporozhye medical journal*, 3, 122 [in Ukrainian].
- [8] Voloshyn, N. A., Karzow, M. V., Grigoreva, E. A., Kusch, O. G., Medvedev, A. E., & Popravko, M. I. (2002). Vnutritroboe vvedenie antigena – model' dlya izucheniya processov morfoheneza limfoidnykh organov [Intrauterine antigen injection – a model for studying the processes of morphogenesis of lymphoid organs]. *Tavrisheskij mediko-biologicheskij vestnik*, 5(3), 43–46 [in Russian].
- [9] Voloshin, N. A., & Grigor'eva, E. A. (2011) Timus novorozhdennykh [Thymus of newborns]. *Zaporizhzhia: ZGMU* [in Russian].
- [10] Sviridov, A. I. (1966) Anatomicheskij atlas limfaticeskikh kapillyarov [Anatomical atlas of lymphatic capillaries]. Kyiv: Zdorovya [in Russian].
- [11] Yarinin, A. A., Pinchuk, V. G., & Grinevich, Yu. A. (1991) Struktura tymusa I differencirovka T-limfocitov [Thymus structure and differentiation of T-lymphocytes]. Kyiv: Nauka [in Russian].

Information about authors:

Grygorieva O. A., MD, PhD, DSc, Professor,
Head of the Department of Human Anatomy, Operative Surgery and Topographic Anatomy, Zaporizhzhia State Medical University, Ukraine.

Apt O. A., MD, PhD, Associated Professor of the Department of Human Anatomy, Operative Surgery and Topographic Anatomy, Zaporizhzhia State Medical University, Ukraine.

Відомості про авторів:

Григор'єва О. А., д-р мед. наук, професор, зав. каф. анатомії людини, оперативної хірургії та топографічної анатомії, Запорізький державний медичний університет, Україна.

Апт О. А., канд. мед. наук, доцент каф. анатомії людини, оперативної хірургії та топографічної анатомії, Запорізький державний медичний університет, Україна.